

DECREASE (EA2182): Delineation of Target Volumes and Critical Structures

Clinical Target Volumes

Pictorial examples of the example case below and other cases can be found at eContour:
<http://econtour.org/cases/DECREASE/>.

1. General Description

The descriptions below give rationale for our definitions of elective lymph nodal regions that comprise the CTVn. These descriptions are informed by published guidelines for IMRT planning in anal cancer from RTOG,¹ the Australian Gastrointestinal Trials Group (AGITG),² as well as the United Kingdom.³ In addition, these CTVn definitions for DECREASE incorporate recommendations from MRI-based imaging studies using iron nanoparticles to define the anatomic location of pelvic lymph nodes in relationship to vessels.⁴⁻⁷ Please also refer to an imaging atlas for descriptions of pelvic lymph node regions and drainage patterns.⁸

Generally, CTVn should be modified to exclude bone and muscle. Anal cancer guidelines do not recommend deleting the bowel space from CTVn, which reflects the important role that elective nodal radiation serves in this disease and the uncertainty in daily location of the bowel versus vascular/nodal space. Therefore, we recommend following the UK guidelines, which specify that expansions around the pelvic vessels should be made which extend into bowel, but that CTVn should not extend more than 1 cm into the adjacent organs including bowel or bladder (<http://analimrtguidance.co.uk/National-Guidance-IMRT-Anal-Cancer-V4-Jan17.pdf>).³ Several guidelines recommend including visible lymph nodes or lymphoceles that are located outside of standardized boundary definitions as part of CTVn, especially in the external iliac and inguinal LN regions, where borders are less well defined.^{1,2,4} However, it is not clear how far beyond standardized boundaries to expand CTVn to include adjacent lymph nodes. Therefore, these decisions will be left up to the treating physician. Please see Section I: "Lateral External Iliac Branch Modification" and Section L: "Inguinal Extension" below for an example relating to this controversy.

2. Step-by-Step Contouring

Please follow step-by-step directions for creating the contours for CTVp and CTVn. Each step is included as a separate contour in the case examples given for eContour. However, there is no need to submit separate contours for each step for central review. The contours for CTVp and CTVn should reflect a summation of the individual steps described below.

The pictures below are taken from the following case:

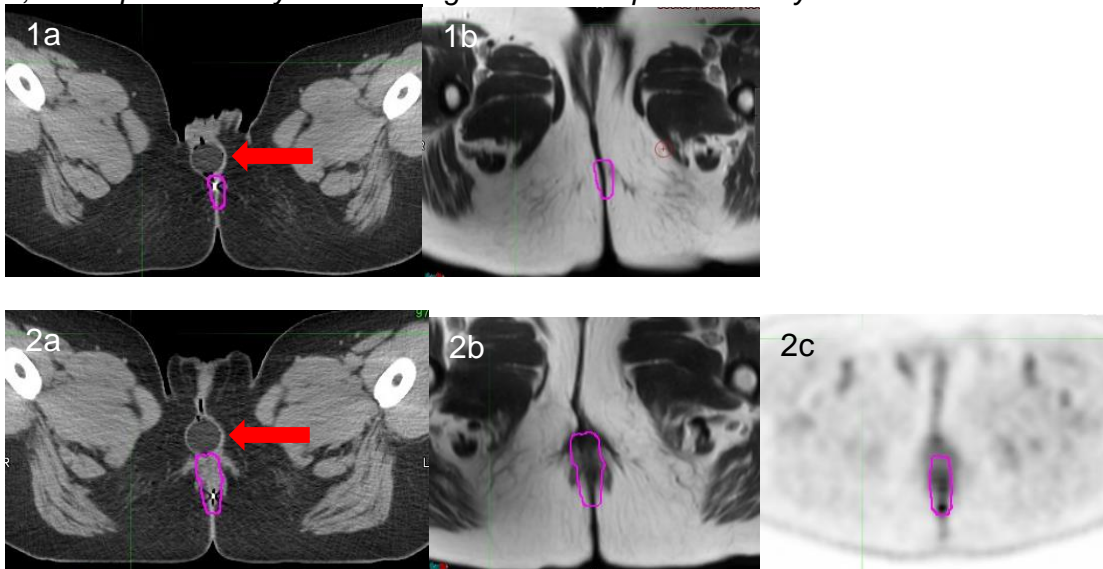
50 y.o. woman with multifocal T1N0 anal margin SCC with a history of early-stage vulvar cancer three years prior status post surgery alone. Exam under anesthesia with high resolution anoscopy and colposcopy revealed two condylomas which were excised (each measuring <1cm), one in the perineal body and a second located at the anal verge involving hemorrhoidal tissue. There were no abnormalities within the anal canal. Pathology revealed invasive squamous cell carcinoma within both condylomas with positive margins. CT chest/abdomen/pelvis did not reveal any concerning findings; a left external iliac LN was visualized with a short axis of 1cm with fatty hilum and was felt to be benign. MRI pelvis was normal. PET/CT didn't reveal any concerning uptake in LN and revealed mild uptake at the perineal resection site and within the anal canal, felt to represent post-surgical changes.

CTVp

a) GTV_dose (magenta contour)

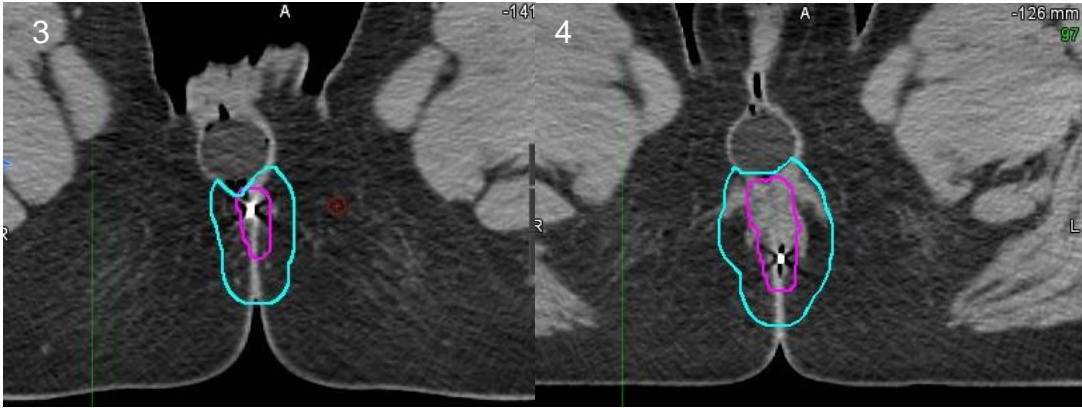
Draw the gross tumor volume (GTV) to include the gross anal/perianal primary tumor volume as documented by clinical information, digital exam, endoscopic findings, biopsy results, and radiographic findings. All areas of perianal skin involvement should be marked with radiopaque markers/wires at the time of CT simulation and should be included in the contour.

Skin involvement is defined as scars from positive biopsy or excision sites and/or areas with erythema and ulceration on visualization, as well as thickening, induration or edema on palpation. From the case example described above, the BB skin marker in Picture 1a was placed at the site of the scar in the perineal body. Slightly superior to this, the second BB in Picture 2a is located at the second scar near the anal verge. There are no abnormalities seen on T2-weighted MRI scans fused to the CT planning scan (Pictures 1b and 2b). There was mild uptake on PET/CT seen within the perineum resection bed in Picture 2c, which was also included in the contour for GTV_dose. Note that the CT planning scan (Pictures 1a and 2a) was obtained in the frog-leg position with a vaginal dilator in place (red arrow), while the MRI and PET/CT were obtained in straight-leg position without a dilator. The fusions in Pictures 1, 2, and 5 preferentially focus on alignment of the perineal body and anal canal.



b) GTV_dose + 1cm (cyan contour)

Expand the GTV_dose contour by 10 mm in all directions, except no expansion into bone / air, or beyond the skin surface. If a patient is using a vaginal dilator during RT, trim the contour off the vaginal dilator on axial slices that do not contain the bladder and/or rectum (demonstrated in Pictures 3 and 4). On axial slices containing the bladder or rectum, do not trim the GTV_dose + 1cm contour off the dilator because there could be differences in positioning due to bladder and/or rectal filling. Please refer to Picture 7 below to see an example of where the CTVn contour extends into the vaginal dilator once the bladder is visualized.



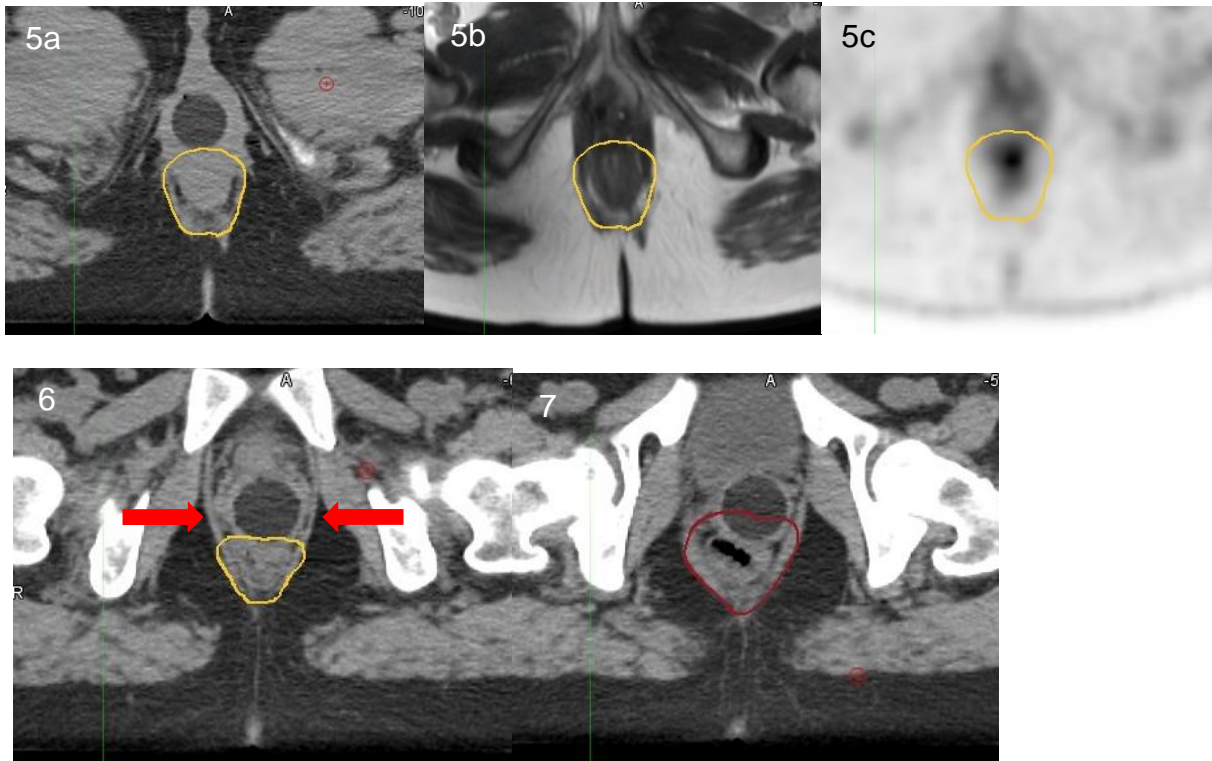
c) CTVp (yellow contour)

Create the final contour CTVp by expanding the GTV_dose + 1cm contour to include the entire anal canal to its outer border, the internal and external sphincter muscles, and the contiguous puborectalis muscle that is directly surrounding the anal canal in the lateral and posterior location. Please include the entire mesorectum in the CTVp contour at levels containing the rectum.

The ischiorectal fossa should only be included in CTVp in the unusual event of a primary tumor that infiltrates > 5 mm outside the external anal sphincter, puborectalis or other muscles of the levator ani, or for tumor that extends into the ischiorectal fossa based on clinical exam or diagnostic imaging (<http://analimrtguidance.co.uk/National-Guidance-IMRT-Anal-Cancer-V4-Jan17.pdf>).³

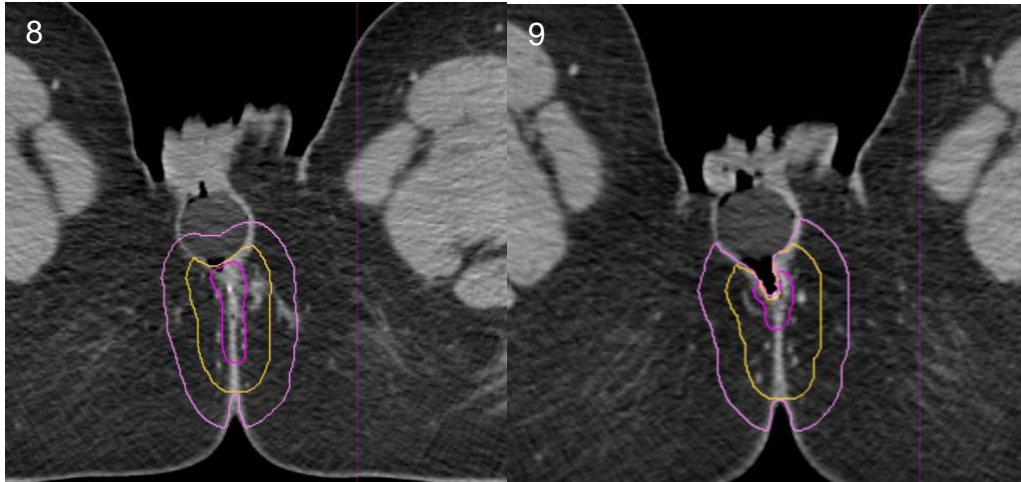
The anal canal extends from the anal verge (defined by the radio-opaque marker placed at the time of CT simulation scan) superiorly to the anorectal junction (located approximately 3-4 cm from the anal verge marker). Please see the transition between the anal canal in Picture 6 to the rectal junction in Picture 7. Starting in Picture 7, the maroon contour defines the inferior extent of CTVn to cover the mesorectum. Note that CTVn extends 1cm into the vaginal dilator at this level because the bladder is present.

For the CTVp, please include the contour in b) plus the entire anal canal, internal and external sphincter muscles and the puborectalis muscle that is directly surrounding the anal canal in the lateral and posterior location. All of these layers are visualized on the T2-weighted MRI images in Picture 5b. The puborectalis muscle originates on both sides of the pubic symphysis and forms a sling around the anorectum (red arrows in picture 6). Please include the puborectalis muscle in the contour because the external sphincter muscle is continuous cranially with the puborectalis muscle and the puborectalis surrounds and is adherent to the anal canal. However, it is not necessary to cover other muscles of the levator ani located above where the puborectalis attaches to the pubic symphysis. In the case example, there were no abnormalities visualized in the anal canal on the T2-weighted MRI image in 5b and there was nonspecific FDG uptake in the anal canal on the PET/CT image in 5c that did not correlate with any abnormalities on clinical exam. Note that the entire anal canal is included as part of the CTVp.



- d) PTVp
 Add the selected margin between 5 mm – 10mm to CTVp to create PTVp. Please see the DECREASE protocol Section 5.2.5.1: “Definition of Target Volumes and Margins” for a description about factors to consider when selecting appropriate expansion margins for the PTVs. For most cases, 10 mm will be appropriate, as was selected in this example case.
- e) PTVp modified (pink contour)
 Subtract PTVp out of air. PTVp can be trimmed away from the skin surface by 3 mm as long as the volume does not extend inside the CTVp (yellow contour) and there is not gross perianal skin extension of the tumor (i.e. tumor extension beyond the anal verge). If bolus was utilized for perianal skin involvement, then PTVp should extend up to the bolus, but not beyond the skin or into the bolus.

In this example case, we elected not to subtract PTVp by 3mm away from the skin because the primary tumor involved the perianal skin. In Picture 8, where the dilator is located inside the vaginal canal, PTVp extends into the vaginal dilator. More inferiorly in Picture 9, the dilator is inferior to the vaginal introitus (with air separating the dilator and the adjacent perianal skin), so the PTVp only covers the adjacent skin/soft tissue, but not the dilator.

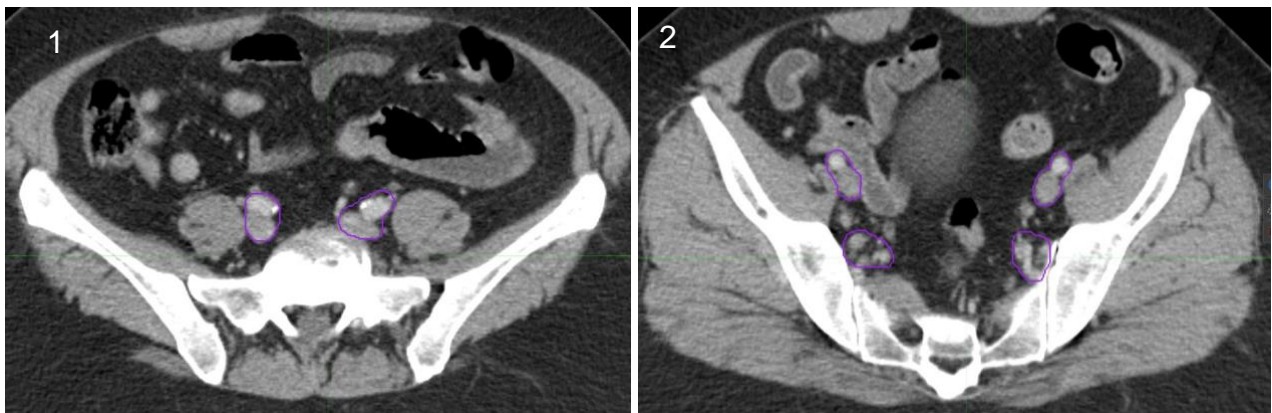


CTVn

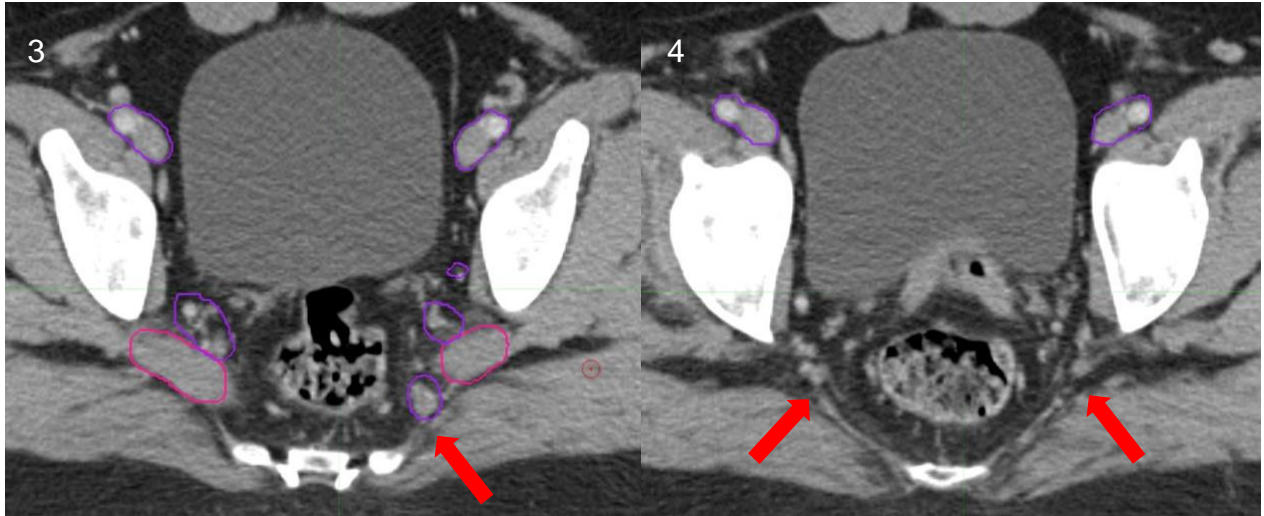
f) Iliac Vessels (purple contour)

Draw a contour around the external and internal iliac vessels including the artery and vein.

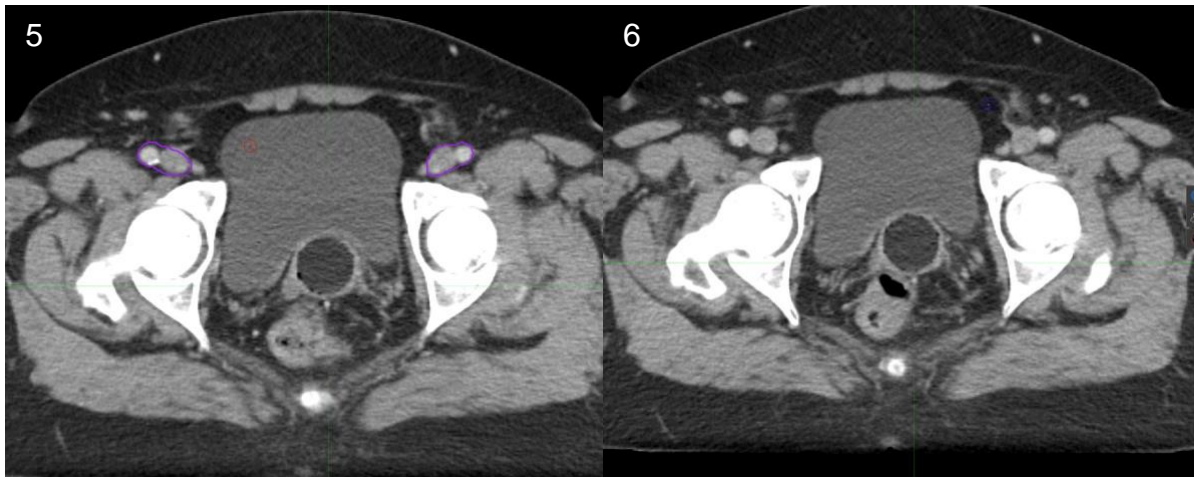
This contour should start superiorly at the L5-S1 interspace for Arm A (Picture 1) or the bottom of the sacroiliac joint for Arm B (Picture 2). The contour may include a portion of the common iliac vessels if the patient is in Arm A, as is depicted in Picture 1. The contour should then bifurcate to include the external iliac vessels and the internal iliac vessels. The internal iliac vessels have many branches which should be included in the contour, including the anterior and posterior divisions and their branches such as the obturator artery.



The portion of the contour including the internal iliac vessels and its branches will end at the bottom of the piriformis muscle (magenta contour) (approximately at a level just above the femoral head) in Picture 3, just above where the inferior gluteal artery (red arrow) exits the pelvis through the greater sciatic foramen in Picture 4.

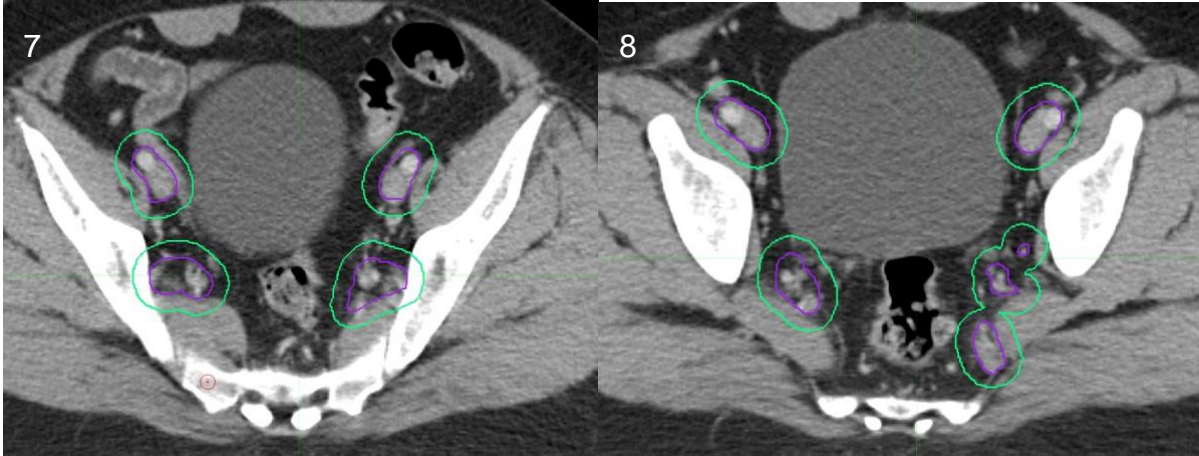


The portion of the contour including the external iliac vessels will continue further inferiorly (compared to the contour containing the internal iliac vessels), as is depicted in Picture 5. The external iliac contour will end at the point where the pelvic brim begins to turn in medially, as depicted in Picture 6.3 Note that this inferior extent will be located approximately below the roof of the acetabulum, near the first slice showing the femoral neck.



g) Iliac Vessels Expansion (green contour)

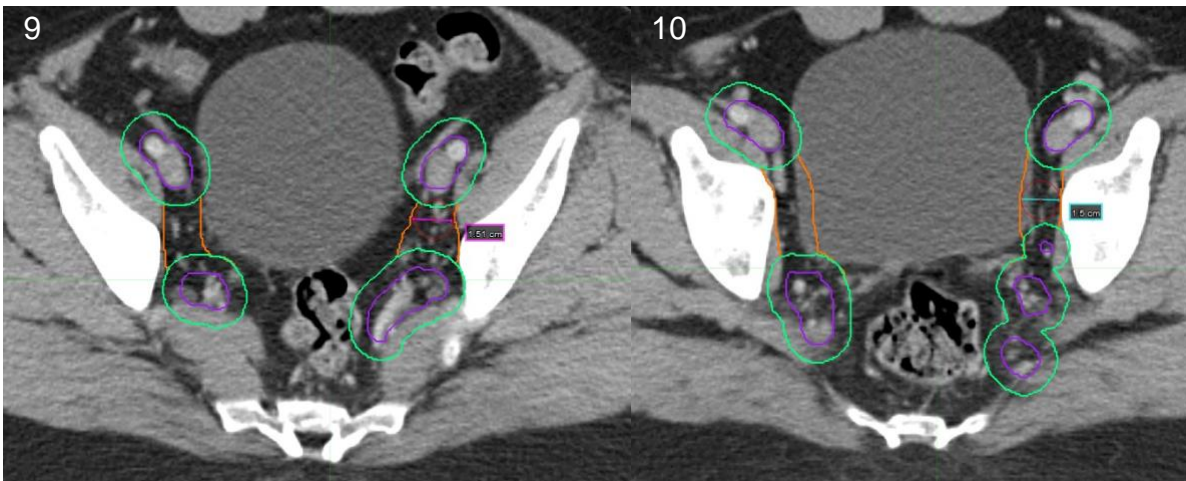
Expand the Iliac Vessels contour by 7 mm in all directions, except do not extend contours superiorly and inferiorly beyond the bony landmarks given in Section F: "Iliac Vessels."



h) Pelvic Sidewall Modification (orange contour)

Join the contours surrounding the external and internal iliac vessels together by using at least a 15 mm diameter “rollerball” (depicted in Pictures 9 and 10) along the medial edges of the iliopsoas or obturator internus muscle. Ensure the lateral border extends to the psoas muscle and pelvic sidewall laterally and the sacrum posteriorly. Choose a larger width if necessary to cover small branching vessels and visible lymph nodes in this region, such as was done for the left pelvic sidewall in Picture 9 (in the region posterior to the rollerball).

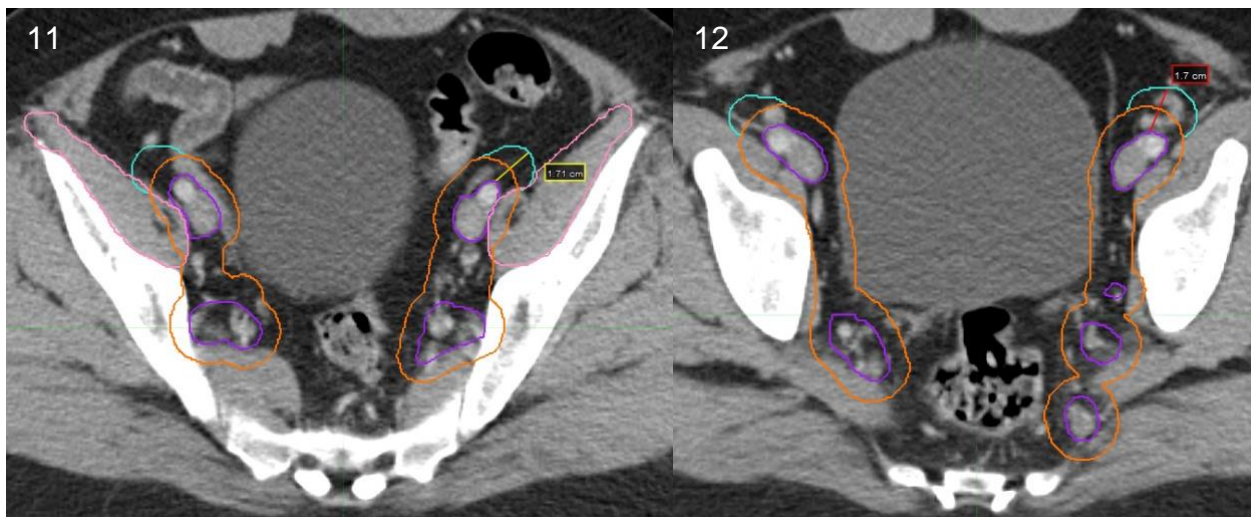We selected a 15 mm diameter strip because an MRI-based imaging study reported that 95% of obturator nodes are covered with a 15 mm wide strip along the pelvic sidewall.⁴ At the level of the femoral heads, where the external iliac contour joins the inguinal region, the space containing the obturator vessels narrows and a narrower strip of 10 mm will suffice to cover the obturator nodes (further described in Section J: “Obturator Modification”).



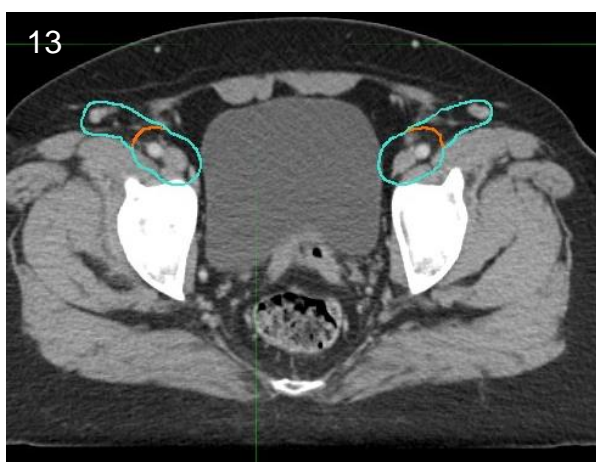
i) Lateral External Iliac Branch Modification (cyan contour)

Extend the contour around the external iliac vessels anterolaterally along the iliopsoas muscle (pink contour in Picture 11) so there is at least 15 -17 mm margin on the external iliac vessels themselves (i.e. add an additional 8-10mm to the Pelvic Sidewall contour). Be sure to cover all visible lymph nodes in this region. Please note in Picture 12 that the visualized lymph nodes in the right and left external iliac regions would not have been covered if not for this expansion.

The iliopsoas muscle (pink contour) is formed by the fusion of the iliacus and psoas muscles, which approximately begins at the bottom of the sacroiliac joint, as is depicted in Picture 11. Starting at this level, extend the external iliac contour in the anterolateral direction as described above.



As the external iliac continues inferiorly and approaches the inguinal region, there may be additional lymph nodes lying further anterior and lateral to this contour, along the iliopsoas muscle. It is controversial as to whether to cover such lymph nodes that extend outside traditional target boundaries, and thus, we will leave it up to the treating physician to decide. In this case, the contour was extended further laterally along the iliopsoas muscle to cover all lymph nodes because it only required slight modification of the contours and was not felt to compromise sparing of radiation dose to organs at risk (Picture 13).



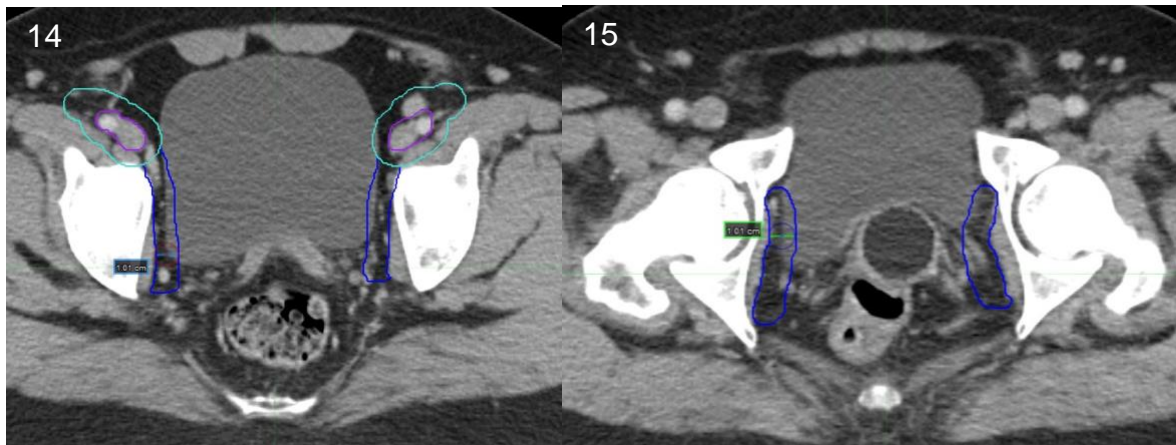
In support of our modifications to cover the lateral external iliac nodes, the RTOG Anorectal Consensus Panel recommends a larger, ≥ 10 mm anterolateral margin be added to the external iliac vessels along the iliopsoas, especially if small vessels or nodes are identified in this area.¹ Indeed, MRI-based imaging studies using iron nanoparticles identify lymph nodes located up to 1.7 cm anterolaterally from the lateral branch of the external iliac vessels.^{4,5} While a 7 mm expansion only covers 40% of lateral external iliac LN, an expansion of 10 mm covers 65%, 15 mm covers 94%, and 17 mm covers 99% of all external iliac LN.^{4,6} On the DECREASE study, we require that at least 15 – 17 mm be added to the lateral branch of the external iliac vessels. It is essential to cover the small vessels and lymph nodes identified in

this area. For some patients, 17 mm will be a more adequate margin to cover visualized vessels/lymph nodes, while in other patients with overlapping bowel space, a margin of 15 mm may be adequate.

j) Obturator Modification (dark blue contour)

To cover the obturator nodes, modify the volume to cover at least a 10 mm strip running along the length of the obturator internus muscle medially until the obturator artery exits the pelvis in the obturator canal. Picture 15 is the last axial slice before the obturator artery exits in its canal.

Start contouring this section of the obturator at the superior aspect where the internal iliac contour ended in Picture 14. At this level, expand the contour surrounding the external iliac vessels posteriorly by covering a 10 mm strip along the obturator internus muscle. Once the contour for the external iliac artery from d) disappears, continue contouring a 10 mm strip along the obturator internus muscle, but limit the anterior extent of the contour to be contained within the bony pelvis. Do not extend the contour laterally past the obturator internus muscle or posteriorly to include the gluteal artery/vessel or sciatic nerve. The medial borders can extend a maximum of 10 mm into the adjacent organs (i.e. bladder or bowel).³



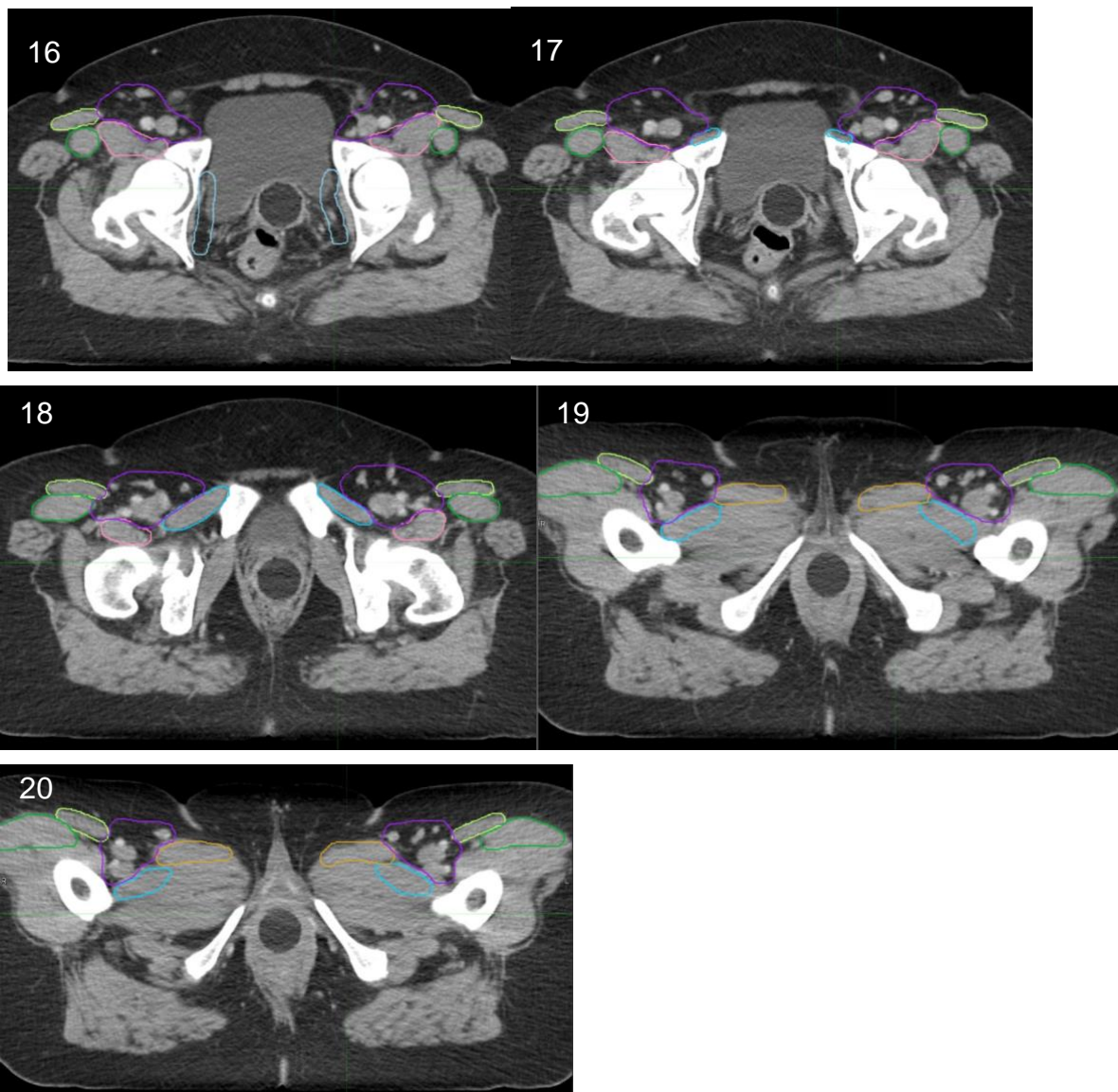
k) Muscle / Bone Exclusion (light blue contour)

Edit the contour in e) to exclude muscle and bone. This edited contour can be seen in Pictures 21-24 below.

l) Inguinal Extension (purple contour)

Both the superficial and deep inguinal lymph nodes of the femoral triangle should be included. Superiorly, begin the modification where the external iliac contour ended in Section F: "Iliac Vessels" and continue inferiorly until the lesser trochanter of the femoral head is visualized. You may extend the contours slightly inferior to the lesser trochanter if there are lymph nodes visualized in this region, as was done for the example case (Picture 20). This is controversial and will be left to the discretion of the treating physician.

The lateral borders include the medial edge of the sartorius muscle (lime green) or iliopsoas muscle (pink). The medial border is the spermatic cord in men and in men and women is the medial third to medial half of the pectineus muscle (light blue) and the medial border of adductor longus muscle (light brown). The posterior border is defined by the pectineus, adductor longus, and iliopsoas (<http://analimrtguidance.co.uk/National-Guidance-IMRT-Anal-Cancer-V4-Jan17.pdf>).³ Please refer to the published atlas for a full description of the boundaries of the inguinal lymphatics.⁸



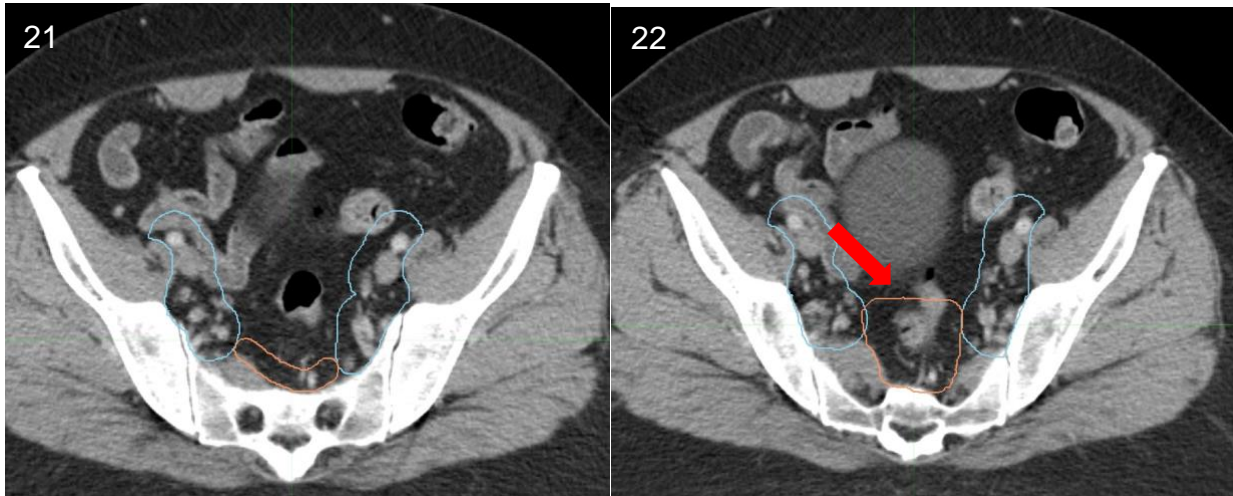
m) New Presacral / Mesorectal Contour (peach contour)

Draw a new joint contour to include both the presacral and mesorectal nodal spaces since they are contiguous. The mesorectal space should include the mesorectum and perirectal lymphatics contained within the mesorectal fascia. The mesorectal fascia is difficult to visualize on CT and better defined on a fat-saturated T2 MRI scan, if that is available. Given that the mesorectal fascia can be difficult to visualize the following boundaries described below should be utilized. This contour should start superiorly at the L5-S1 interspace for Arm A or the bottom of the sacroiliac joint for Arm B.

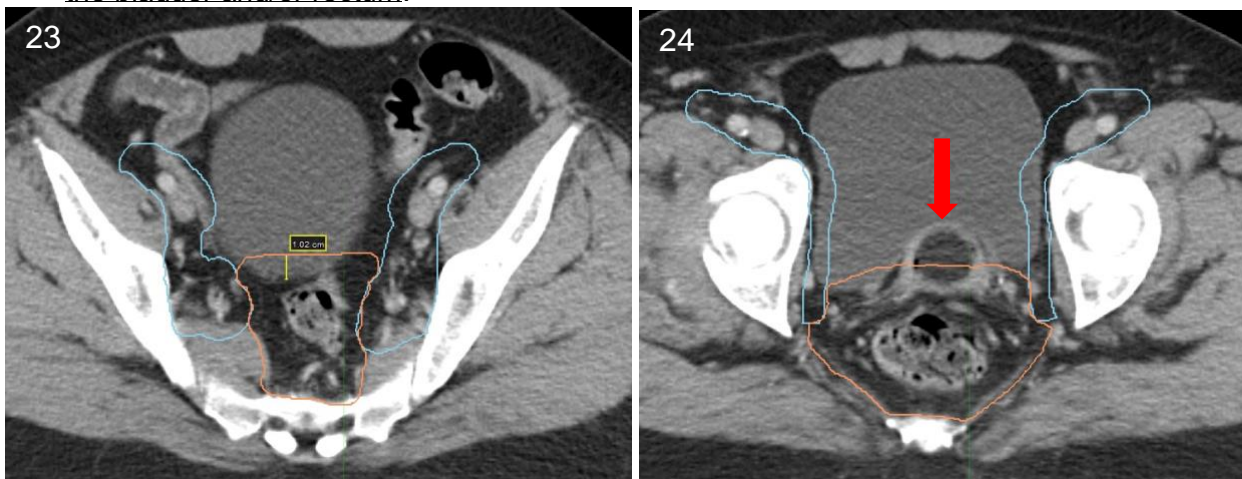
- Superior border:
 - For **Arm A**, the contour starts superiorly at L5-S1 to cover the presacral region, which should be drawn as a 10 mm strip of tissue anterior to the sacrum. Posteriorly, it will extend to the anterior border of the sacral bone, but will not include the sacral hollows.³ Laterally, it will extend to the sacro-iliac joints. Please see an example of this contour in Picture 20 at the level of S1.

Usually inferior to L5-S1, at the level of the recto-sigmoid junction (indicated as a red arrow in Picture 21), the mesorectal fat space begins and is contiguous with the presacral space. Starting at this level, the joint contour should include both the 10 mm strip anterior to the sacrum and the mesorectal fat space bounded by the mesorectal fascia.

- For **Arm B**, the joint contour starts superiorly at the bottom of the SI joint, a point where both the presacral and mesorectal nodal spaces are typically both present.



- Anterior border: The anterior border of the mesorectal fascia is defined by the interface with the seminal vesicles, prostate, vagina, cervix, uterus and/or bladder. However, an internal margin of 10mm should be added to this anterior mesorectal border on axial slices containing the bladder, seminal vesicles or uterus (as depicted in Picture 23) to account for the effect of differences in bladder and/or rectum filling from day to day.^{1,2} In patients using a vaginal dilator (indicated by a red arrow in Picture 24) during RT, the contour should include a 10mm internal margin extending into the vaginal dilator on axial slices containing the bladder and/or rectum.



- Inferior border: the anorectal junction, where the levators fuse with the external anal sphincter such that the mesorectal fat space is no longer seen (as in Picture 7 in Section C: “CTVp” above).
- Posterior border: the contour should extend to the anterior border of the sacral bone, but will not include the sacral hollows.³
- Lateral border: ileum, piriformis and obturator muscles

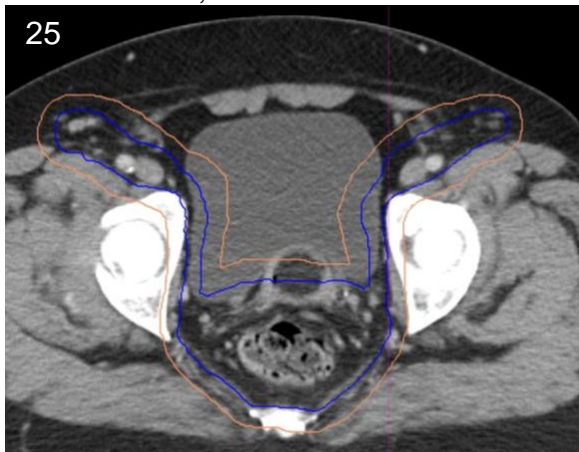
n) CTVn (dark blue contour)

Join the Inguinal Extension contour with the New Presacral / Mesorectal contour to create CTVn and smooth the junctions between contours. Expand the contour to include all visible lymph nodes and exclude muscle and bone. Be sure that CTVn does not overlap with CTVp. Please be sure that CTVn starts superiorly at the L5-S1 interspace for Arm A or the bottom of the sacroiliac joint for Arm B.

o) PTVn (peach contour)

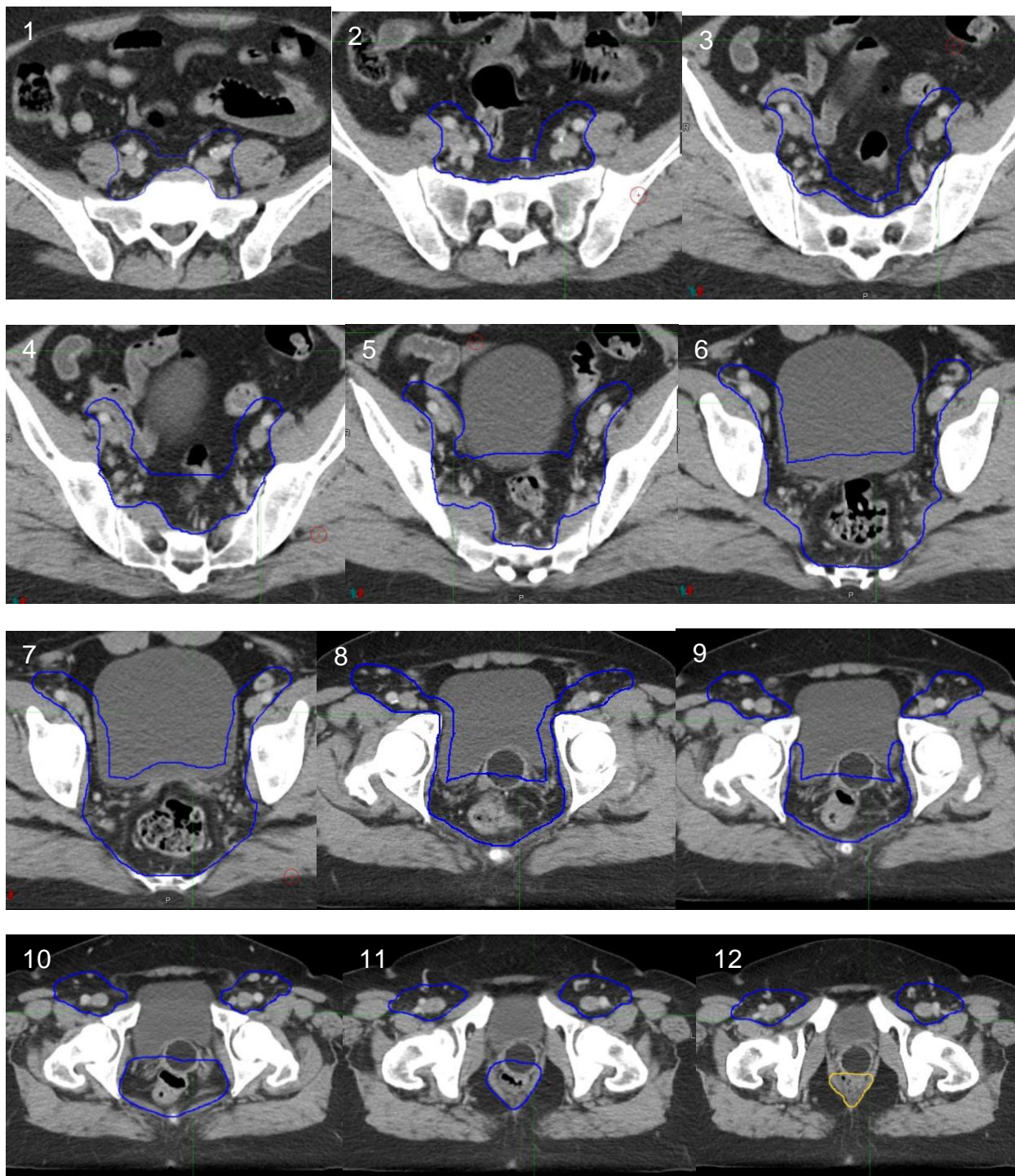
Expand CTVn by 5 – 10 mm in order to create PTVn. In most cases, a 7 mm expansion will be sufficient, as was utilized in the example case. Subtract the volume containing PTVp from the PTVn contour in any areas that overlap. Please see the DECREASE protocol Section 5.2.5.1: “Definition of Target Volumes and Margins” for a description about factors to consider when selecting appropriate expansion margins for the PTVs.

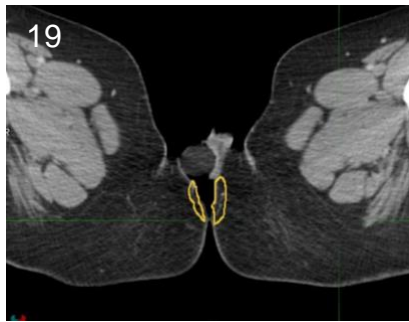
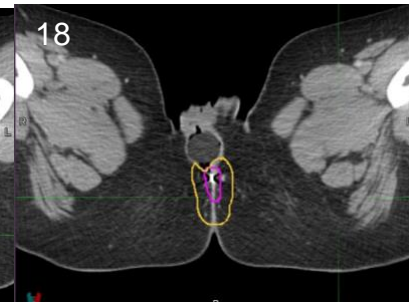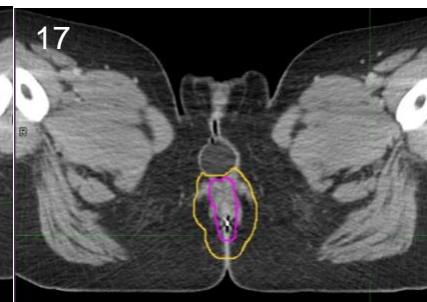
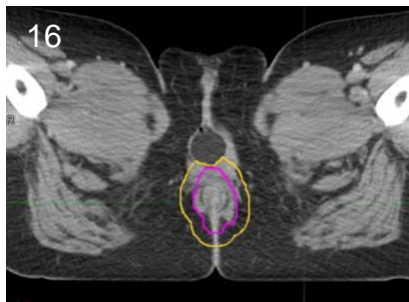
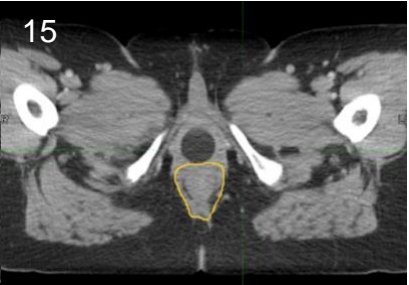
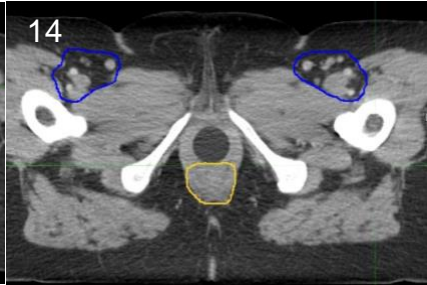
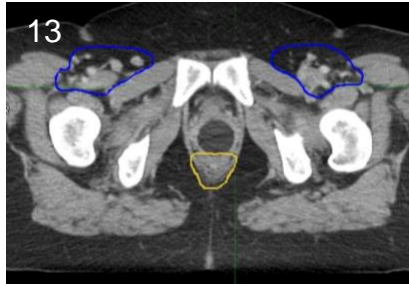
The anterior border for PTVn should be subtracted 5 mm from the skin in the inguinal region for most patients. However, a 3 mm subtraction may be preferable if lymph nodes are visualized directly underlying the skin, which can happen in very thin patients and/or those positioned in the prone position, where there can be a degree of compression of the soft tissue in the groin. In the case example, there was plenty of tissue to separate PTVn from the skin surface, so no subtraction was necessary (Picture 25).



3. CTVp and CTVn Contour Summation

Please see the summation for CTVp (yellow) and CTVn (dark blue) contours. GTV_dose is depicted as well (magenta). The images are ordered from the superior to inferior extent.





References

1. Myerson RJ, Garofalo MC, El Naqa I, et al. Elective clinical target volumes for conformal therapy in anorectal cancer: a radiation therapy oncology group consensus panel contouring atlas. *Int J Radiat Oncol Biol Phys*. 2009;74(3):824-830.
2. Ng M, Leong T, Chander S, et al. Australasian Gastrointestinal Trials Group (AGITG) contouring atlas and planning guidelines for intensity-modulated radiotherapy in anal cancer. *Int J Radiat Oncol Biol Phys*. 2012;83(5):1455-1462.
3. Muirhead R, Adams RA, Gilbert DC, et al. Anal cancer: developing an intensity-modulated radiotherapy solution for ACT2 fractionation. *Clin Oncol (R Coll Radiol)*. 2014;26(11):720-721.
4. Taylor A, Rockall AG, Reznick RH, Powell ME. Mapping pelvic lymph nodes: guidelines for delineation in intensity-modulated radiotherapy. *Int J Radiat Oncol Biol Phys*. 2005;63(5):1604-1612.
5. Dinniwell R, Chan P, Czarnota G, et al. Pelvic lymph node topography for radiotherapy treatment planning from ferumoxtran-10 contrast-enhanced magnetic resonance imaging. *Int J Radiat Oncol Biol Phys*. 2009;74(3):844-851.
6. Vilarino-Varela MJ, Taylor A, Rockall AG, Reznick RH, Powell ME. A verification study of proposed pelvic lymph node localisation guidelines using nanoparticle-enhanced magnetic resonance imaging. *Radiother Oncol*. 2008;89(2):192-196.
7. Shih HA, Harisinghani M, Zietman AL, Wolfgang JA, Saksena M, Weissleder R. Mapping of nodal disease in locally advanced prostate cancer: rethinking the clinical target volume for pelvic nodal irradiation based on vascular rather than bony anatomy. *Int J Radiat Oncol Biol Phys*. 2005;63(4):1262-1269.
8. Lengele B, Scalliet P. Anatomical bases for the radiological delineation of lymph node areas. Part III: Pelvis and lower limbs. *Radiother Oncol*. 2009;92(1):22-33.